

Volume 2, Number 2 – January 31, 2008

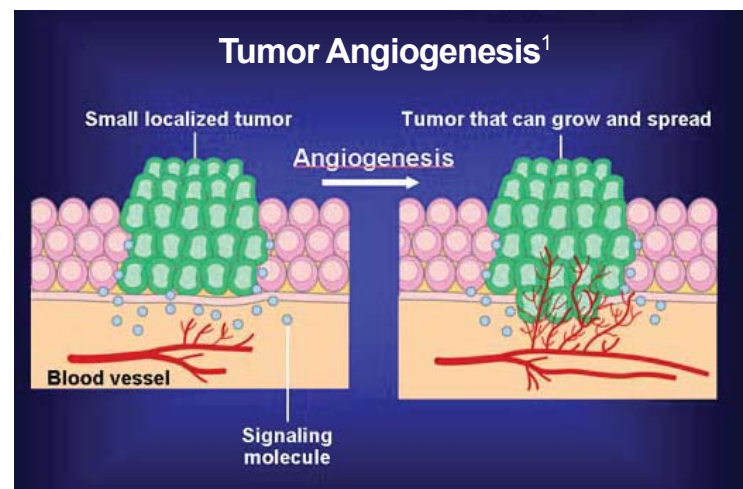
RADIOLOGY: ANGIOGENESIS AND IMAGING

DEFINITION

Normal and Malignant Growth Within the Human Body

Angiogenesis is the formation of new blood vessels. This can occur in several different situations:

- **Normal growth**
 - Formation of blood vessels in a growing fetus
 - Formation of blood vessels in the uterine lining, to allow for menstruation and pregnancy
- **Wound healing**
 - New blood vessels form in the healing process, to regenerate damaged tissue
- **Tumor growth**
 - So that malignant tumor cells can grow and divide more rapidly, they form new blood vessels



MALIGNANT TUMORS

Angiogenesis in Cancer

In a healthy person, activator and inhibitor molecules closely regulate angiogenesis. Most of the time, the inhibitors outnumber the activators, so that new blood vessels are not made. In situations where new blood vessels are needed, such as pregnancy or wound healing, the activator molecules are created and released.

Malignant tumors have the ability to produce these activator molecules, such as vascular endothelial growth factor (VEGF), to induce the formation of new blood vessels, allowing for cell multiplication and tumor growth.

Angiogenesis is a key factor in the growth of malignant tumors. Studies have shown that without the formation of new blood vessels, tumor growth stops. This is the basis of many medical treatments for cancer. For example, several new drugs being developed for cancer treatment are inhibitors of angiogenesis. Within the realm of radiology, angiography (see *WCC Note*, Volume 1, Issue 10) can be used to localize the blood vessel that feeds a tumor. The radiologist can then place coils or packing material in the blood vessel to stop flow to the tumor. This will cause cessation of growth and can cause the death, or necrosis, of the tumor.

Imaging's Role

Because angiogenesis is vital to the growth of a cancer, it can be extremely useful to physicians to assess the extent of angiogenesis within a tumor. This is especially valuable to evaluate the effects of cancer therapy, by observing whether the amount of blood vessels in a tumor decreases after treatment.

The small blood vessels created within tumors are almost always microscopic in size, and thus not directly visible on CT or MRI. However, one can use indirect or “surrogate” markers that indicate how much blood flow is going to a tumor, such as the amount of contrast enhancement, the amount of oxygen, and the amount of blood volume.²

Using Contrast Agents

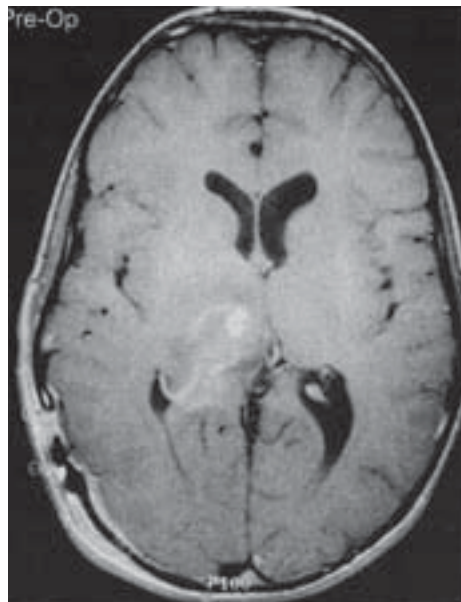
By administering an intravenous contrast agent – a liquid injected into the veins that follows the bloodstream and appears bright on images – a radiologist can indirectly assess the amount of blood flow going to an organ or tumor. The amount of flow to a tumor is indicative of both angiogenesis and of vascular permeability, both of which are increased in malignant tumors. Rapid, strong enhancement can be an indicator of malignancy. A decrease in the amount of contrast enhancement of a tumor after treatment may indicate a positive response.

The contrast agent traditionally used in MR imaging is *gadolinium (gadopentate dimeglumine)*, which is considered a small-molecular contrast agent. Gadolinium-enhanced MRI has proven to be useful in distinguishing benign from malignant tumors in most organs, including the breast, brain, liver, colon, prostate, and many others. Studies on perfusion MRI with gadolinium have shown some correlation between the amount of angiogenesis and gadolinium enhancement.³

In many studies, however, large-molecular contrast agents have been found to be more accurate in assessment of tumor vascularity and angiogenesis. This is because the gadolinium molecules are small enough to diffuse through normal vessels, while the large-molecular agents are unlikely to leak through a normal vessel.^{5, 6} Commonly used large-molecular agents include ultra-small superparamagnetic iron oxide (USPIO) and albumin-bound gadolinium. Recent studies have shown large-molecular MR perfusion imaging to be accurate in assessment of angiogenesis in several cancers, including leukemia, soft-tissue sarcoma, and many others.^{7, 8}

CT perfusion imaging works on the same principle, and also has been proven accurate in assessing the vascularity and response of many tumors to chemotherapy, including renal cell carcinoma, head and neck cancer, and rectal carcinoma.^{2, 9, 10, 11}

Ultrasound, specifically Doppler ultrasound, can give a rough idea of how vascular a tumor is. However, this method is not very accurate at assessing small changes in blood flow.

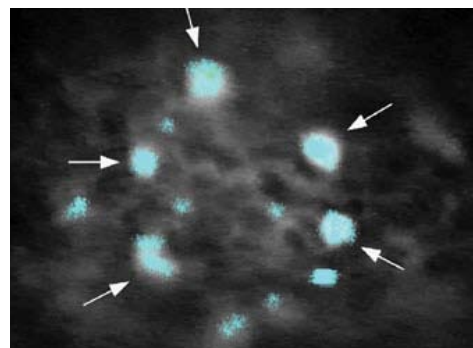


Preoperative gadolinium-enhanced axial MR image of a glioma in the lateral ventricle.⁴

Angiogenesis Imaging Moves Ahead

Molecular imaging uses specially engineered molecules to bind to specific sites and receptors, allowing one to localize areas of molecular action. There are two main types:

- *Targeted contrast agents* are made by linking a contrast agent to a molecule, such as an antibody, which will bind only to a certain target molecule in the body. This allows a radiologist to see exactly where in the body specific molecular interactions are happening, such as the activation of angiogenesis.



Optical image (x250 magnification) of a tumor showing molecular imaging.

- *Smart probes* are the same as targeted contrast agents, except they change chemically once they hit their target. This change can be seen on magnetic resonance imaging.²

an exteriorized metastatic colon cancer-bearing live mouse liver, demonstrating the presence of tumor-recruited macrophages (arrows) into the center of this tumor.

QUANTITATIVE MARKERS

Quantitative Markers Used in MRI & CT to Measure Angiogenesis

- Area under the curve
- Wash-in slope
- Extraction fraction or wash-out (lesion permeability)
- Arterial appearance function – appearance of tumor relative to the heart or aorta
- Signal enhancement ratio – ratio of intensity change relative to normal tissue following contrast injection

NEXT ISSUE: SUMMING UP THE MODALITIES

SOURCES

1. <http://www.cancer.gov/cancertopics/understandingcancer/angiogenesis>
2. Provenzale JM. "Imaging of Angiogenesis: Clinical Techniques and Novel Imaging Methods." *Am. J. Roentgenol.* 2007;188:11-23
3. Buadu LD, Murakami J, Murayama S, et al. "Breast Lesions: Correlation of Contrast Medium Enhancement Patterns on MR Images with Histopathologic Findings and Tumor Angiogenesis." *Radiology* 1996;200: 639-649.
4. http://www.medscape.com/viewarticle/405720_5
5. de Lussanet QG, Backes WH, Griffioen AW, et al. "Gadopentetate Dimeglumine versus Ultrasmall Superparamagnetic Iron Oxide for Dynamic Contrast-Enhanced MR Imaging of Tumor Angiogenesis in Human Colon Carcinoma in Mice." *Radiology* 2003;229:429-438.
6. Daldrup H, Shames DM, Wendland M, et al. "Correlation of Dynamic Contrast-Enhanced MR Imaging with Histologic Tumor Grade: Comparison of Macromolecular and Small-Molecular Contrast Media." *Am. J. Roentgenol.* 1998;171:941-949.
7. Matuszewski L, Persigehl T, Wall A, et al. "Assessment of Bone Marrow Angiogenesis in Patients with Acute Myeloid Leukemia by Using Contrast-Enhanced MR Imaging with Clinically Approved Iron Oxides: Initial Experience." *Radiology* 2006;242:217-224.
8. Persigehl T, Bieker R, Matuszewski L, et al. "Antiangiogenic Tumor Treatment: Early Noninvasive Monitoring with USPIO-enhanced MR Imaging in Mice." *Radiology* 2007;244:449-456.
9. Faria SC, Ng CS, Hess KR, et al. "CT Quantification of Effects of Thalidomide in Patients with Metastatic Renal Cell Carcinoma." *Am. J. Roentgenol.* 2007;189:378-385.
10. Bellomi M, Petralia G, Sonzogni A, et al. "CT Perfusion for the Monitoring of Neoadjuvant Chemotherapy and Radiation Therapy in Rectal Carcinoma: Initial Experience." *Radiology* 2007;244:486-493.
11. Wang JH, Min PQ, Wang PJ, et al. "Dynamic CT Evaluation of Tumor Vascularity in Renal Cell Carcinoma." *Am. J. Roentgenol.* 2006;186:1423-1430.



THE WCC NOTE™: Volume 2, Number 2 – January 31, 2008
Contributing Editors: Resham R. Mendi, M.D. (newsletter@wcclinical.com)
and Stephen J. Pomeranz, M.D. (newsletter@wcclinical.com)
Managing Editor: Rod Willis (newsletter@wcclinical.com)
Designer: Tom Anneken

Contents of this electronic newsletter are copyright © 2008 by WorldCare Clinical, LLC, 7 Bulfinch Place, P.O. Box 8908, Boston, MA 02114. All article summaries are compiled from public sources. For more information on WorldCare Clinical, please go to www.wcclinical.com.